


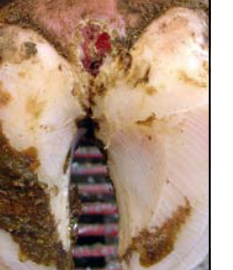





























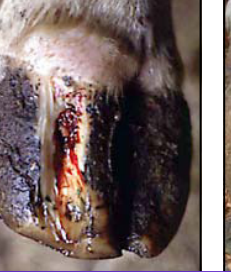










BOVINE HOOF LESION IDENTIFICATION AND SEVERITY SCORE SHEET

Severity Score	A = Abscess	B = Bruise	C = Corn	D = Dermatitis / Heel Wart	E = Heel Erosion	F = Fissure	G = Digital Sepsis
	White Line Abscess	White Line Hemorrhage	Inter-digital Hyperplasia	Digital dermatitis	Hel Horn Erosion	White Line Fissure	Deep Digital Sepsis
1 = Mild							
	Small amount of pus, not extending to the coronary band	Localized redness in white line of outer claw	Grape size growth between claws	Small dime size moist area in the inter-digital cleft	Small pock marks of erosion or small fissure	Small fissure in white line close to heel	Obvious signs of sepsis from a complicated sole ulcer (severe)
2 = Moderate							
	Large amount of pus but does not emerge at coronary band	Redness in white line of one or both claws	Growth larger than a grape, but confined between claws	Strawberry granuloma larger than a dime	Single large fissure across the entire heel	Wide fissure but does not extend to coronary band	Asymmetrical swelling around coronary band
3 = Severe							
	Pus emerging at coronary band	Hemorrhage with separation	Large tumor like corn	Verrucose tentacles growing out of granuloma	Multiple fissures extending across heel with extensive erosion	Large fissure extending to coronary band without pus	Separation around coronary band (severe)

BOVINE HOOF LESION IDENTIFICATION AND SEVERITY SCORE SHEET

Severity Score	H = Hemorrhage	P = Phlegmon / Foot Rot	S = Sole Fracture / Heel Ulcer	T = Toe Ulcer	U = Ulcer	V = Vertical Wall Crack	Y = Horizontal Fissure
	Sole Hemorrhage	Inter-digital Necrobacillosis	Sole Fracture	Toe Ulcer	Sole Ulcer	Vertical Fissure	Horizontal Fissure
1 = Mild	 Superficial hemorrhage in typical site	 Slight separation of inter-digital skin with little swelling	 Small fissure at junction of heel and sole, not extending into heel	 Small fissure at white line in toe area	 Deep hemorrhage with exposure of corium less than dime area	 Wall crack without associated pain	 Small fissure on one claw
2 = Moderate	 Deep hemorrhage in typical site	 Split in inter-digital skin with swelling confined between claws	 Large fissure with underrun sole confined to heel area	 Disintegration of sole horn in toe area extending to corium	 Exposed corium more than a dime	 Painful crack starting at coronary band	 Small fissure on both inner and outer claw
3 = Severe	 Diffuse extensive hemorrhage across sole	 Deeply erosive lesion with swelling around the coronary band	 Separation of a large area of sole	 Widespread necrosis of corium in the toe extending to bone	 Prolapse of corium through full thickness defect	 Painful crack extending from coronary band to toe to depth of corium	 Large fissure on both inner and outer claw within 1.25 inches of sole surface