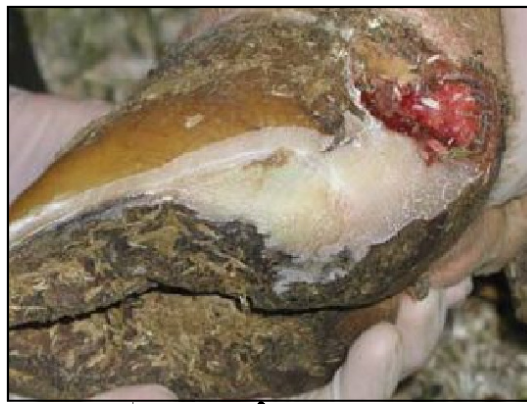

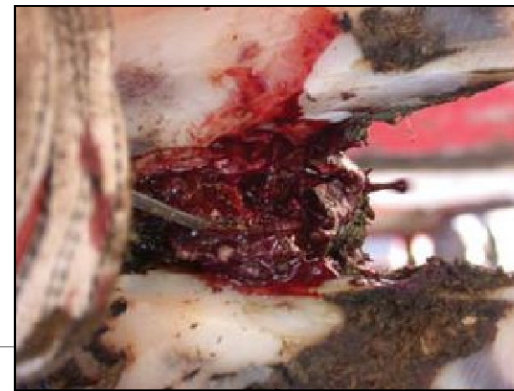White Line disease

- Infection in soft “white line area”
- Causes swelling, normally in heel of only one claw
- Can spread to joints and tendons



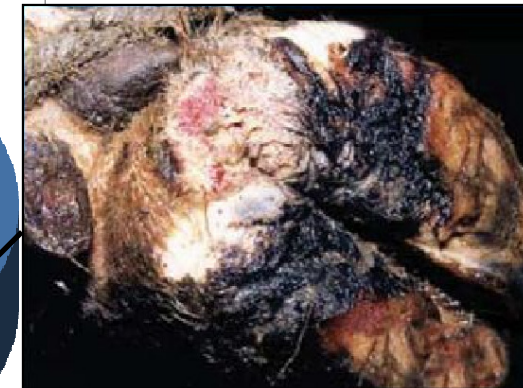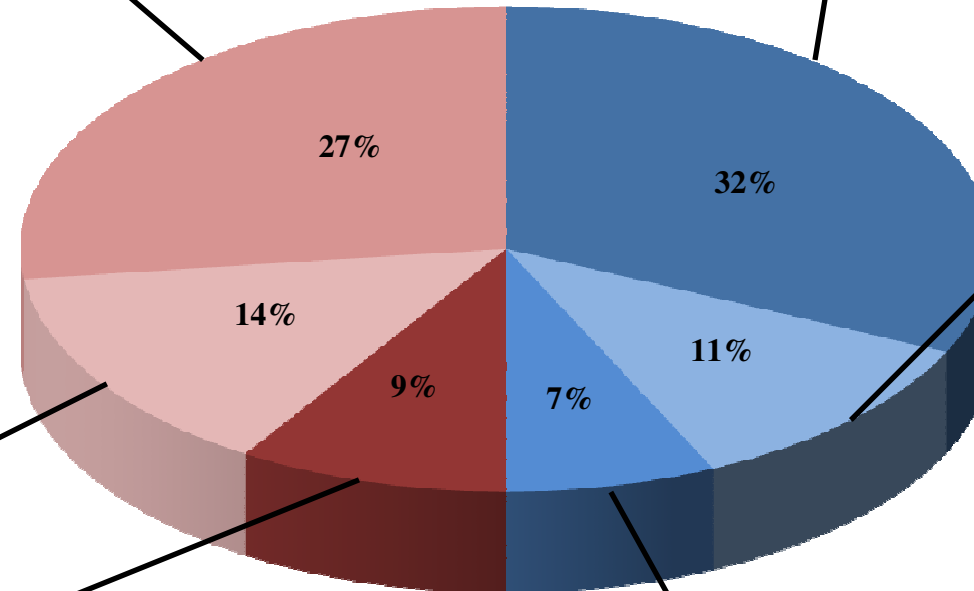
Hoof Rot

- Painful infection of the skin between the claws
- Common in wet, muddy, dirty conditions
- Swelling of entire hoof and separation of claws
- Bad odor, fever
- Treat with antibiotics
- *Control by* : keeping environment clean and maintaining proper foot baths



Laminitis

- Painful inflammation of the hoof
- Poor nutrition
- Damaged blood vessels in claw
- May lead to ulcers, white line disease and heel erosion

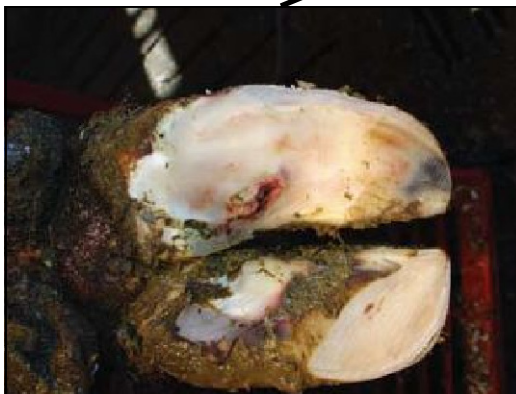

Digital Dermatitis

- Painful lesions on heel
- Caused by *Treponema* bacteria
- Occurs in wet, muddy, dirty conditions
- Interdigital dermatitis - Lesions between toes
- Treat with topical antibiotics
- *Control by* : cleaning up environment and maintaining proper foot bath

Sole Ulcer

- Painful sore inside the hind claw
- Often revealed during trimming
- Caused by abrasive surfaces and lack of proper hoof trimming
- Apply block to sound claw to relieve pressure



Heel Erosion

- Bulb of heel becomes pitted and ridged
- Loses shock-absorbing ability and stability
- Related to manure slurry, laminitis and dermatitis
- Steep slopes can aggravate
- *Control by* : cleaning up environment, maintaining proper foot bath, and correct and timely foot trimming

